



EVALUATION OF FOCAL BREAST LESIONS USING ULTRASOUND ELASTOGRAPHY

Dr. Anu Atul Kaushik

Associate Professor Dept. of Radio-diagnosis Rama Medical College, Hospital and Research Center Hapur.

Conflicts of Interest: Nil

Abstract:

Introduction: Women's breast cancer, from the past era especially, has been a worldwide public health problem. Breast cancer is considered as women's primary cancer and causes high morbidity and mortality that induce attention for disease preventive programs. From different cross-sectional studies specified the effectiveness of chemo-preventive measures for breast cancer in high risk women. across all breast cancer risk groups, The relative risk reduction seems similar, however, the absolute risk reduction differs by risk factors for breast cancer and must balance against the potential harms for the decision for the appropriateness of treatment for individual women. Breast is the soft consistency made of fatty tissues that surround the breast glands. There are Different breast lesions are present fibro adenoma is considered the commonest benign tumor whereas the invasive ductal carcinoma is the commonest malignant tumor. Breast cancer has high incidence and its slow evolution before diagnosis which have emitting light to research on new diagnostic techniques. Recently ultrasound elastography is stiffness-based imaging has emerged as a new imaging technique which displays the tissue stiffness i.e. presenting hard or soft color-coded map that overlays the conventional B-mode image. Therefore, by elastography diagnosis can be improved for breast masses whether benign or malignant. **Aim:** The aim of this study was to evaluation of focal breast lesions using ultrasound elastography. **Material and methods:** This are the prospective cross- section study which is carried out on 50 female patients between the age group 20 to 70 years old visiting the ultrasound section of Rama medical College Hospital and Research Center Hapur in the Department of Radiology in a period of more than two year. All the patients were referred to the Department of Radiology were diagnosed to have focal breast lesions by sonography were included in the study. From all patient complete history were taking and thorough clinical examination and ultrasound elastography done in the Department of Radiology in ultrasound section. Semi-quantitative elastography was used as Hitachi 7.5 MHz linear probe. For obtaining correct elastography images, definition of the ROI should be known. Then strain image was allowed analysis of the strain ratio values which were calculated. The results were also confirmed by histopathological examination, follow up and MRI mammography. **Result:** In this study 50 female patients with palpable breast lumps were included having the age group 20 to 70 years with a mean age of 46 years. All patients were evaluated by gray scale ultrasound and sono-elastography examination with multiple different pathological lesions. According to the diagnosis in all the cases the lesions subdivided into 32 benign and 18 malignant lesions according to MRI, histopathological findings and follow up. Ultrasound elastography of breast lesions were done in all the patients' being classified according to modified Ueno and Ito elasticity score system. Benign lesions which had elastography score as 1, 2, 3 and 4 are follow as 7(21.9%) lesions had elastography score 1, 16 (50%) lesions had elastography score 2, 2(6.3%) lesions had elastography score 3 and 7 (21.9%) lesions had elastography score 4. Whereas

Corresponding author: Dr. Anu Atul Kaushik

malignant breast lesions having elastography score 3, 4 and 5 are as follow: 3(16.7%) lesions had elastography score 3, 12(66.7%) lesions had elastography score 4 and 3(16.7%) lesions had elastography score 5. **Conclusion:** For examination of suspected breast cancer elastography should be used as an adjunct to the conventional B-mode examination. Elastography also provided other characterization of breast lesions which improve the specificity for low suspicion lesions achieved at conventional US.

Keywords: Breast lesions, ultrasound elastography operator characteristic analysis.

INTRODUCTION:

From the past era especially for women breast cancer has been a worldwide public health problem. Breast cancer is consider being women's primary cancer and causes high morbidity and mortality that induce attention for disease preventive programs. From different cross-sectional studies specified the effectiveness of chemo-preventive measures for breast cancer in high risk women. across all breast cancer risk groups, The relative risk reduction seems similar, however, the absolute risk reduction differs by risk factors for breast cancer and must balance against the potential harms for the decision for the appropriateness of treatment for individual women^{1,2,3&4}. Breast is a specialized organ which located on the anterior chest wall which consistent of different tissues including fibrous, glandular as well as fatty tissues. Breast is the soft consistency made of fatty tissues that surround the breast glands. There are Different breast lesions are present fibroadenoma is considered the commonest benign tumor whereas the invasive ductal carcinoma is the commonest malignant tumor⁵. Since beginning of the 1990s, term elastography has used in ultrasound that refer to number of different methods for visualizing tissue strain^{6,7}. The property of tissue is intrinsic elasticity that can change due to pathophysiological processes such as inflammation, aging or tumorous processes⁸. Breast cancer has high incidence and its slow evolution before diagnosis which have emitting light to research on new diagnostic techniques^{9,10&11}. Recent establishment elastography has increased the specificity of USG which enabled earlier diagnosis of breast cancer. Quantitative elastography is used with strain ratio (SR) that improves diagnostic

accuracy in cases with equivocal Stavros criteria (stages 3 and 4 BI-RADS). On the basis of their elasticity, USG elastography (SE) differentiates between benign and malignant lesions. Benign lesions have an elasticity which is similar to the surrounding tissue whereas malignant lesions are harder than adjacent tissue¹². Ultrasound elastography (UE) represent the stiffness of tissues¹³. Breast ultrasonography (US) plays a critical role in the field of diagnostic evaluation of palpable breast masses or screening-detected. US with high-frequency transducer are essential for accurate noninvasive diagnosis of differentiating solid cystic breast lesions. In addition to this US is also useful in the examination of young or pregnant symptomatic patients. Ultrasound is the preferable as screening method as it gives high sensitivity for detecting breast cancer in women with dense breast tissue which can detect cancers that is not identified on mammography in asymptomatic women with dense breast tissue. Increasing in US cancer detection is reported in 0.27– 0.46% of women with mammography-negative dense breasts^{14,15}. Nowadays due to development of recent techniques in breast imaging, screening programs and higher degree of health awareness there is relative decreased incidence of breast cancer mortality¹⁶. Recently ultrasound elastography is stiffness-based imaging has emerged as a new imaging technique which displays the tissue stiffness i.e. presenting hard or soft color-coded map that overlays the conventional B-mode image. Therefore, by elastography diagnosis can be improved for breast masses whether benign or malignant¹⁷. Different techniques have been introducing different ultrasound elastography including compression strain imaging, and real-time shear velocity. Nowadays compression

ultrasound elastography is considered as most common technique used in breast imaging¹⁸. There is generated a color map which and is corresponding to the gray-scale ultrasound images. A grading scale used to classify lesions, according to the color signature, has been introduced by Itoh et al¹⁹. The aim of this study was to evaluation of focal breast lesions using ultrasound elastography.

MATERIAL AND METHODS:

This is the prospective cross- section study which is carried out on 50 female patients between the age group 20 to 70 years old visiting the ultrasound section of Rama Medical College hospital and Research center in the Department of Radiology in a period of one year. All the patients were referred to the Department of Radiology were diagnosed to have focal breast lesions by sonography were included in the study. From all patient complete history were taking and thorough clinical examination and ultrasound elastography done in the Department of Radiology in ultrasound section. Semi-quantitative elastography (strain ratio technique) was used as Hitachi 7.5 MHz linear probe ((Hitachi hi visions a virus ultrasound, Model: EZU-MT29-S1, Japan). After US detection of the lesion in B-mode the patient remains in the same supine position. After that color map was generated with the corresponding grey scale ultrasound image after applying a light pressure with the probe. When there were regular waves on the scale at the bottom of the image adequate pressure was identified. For obtaining correct elastography images, definition of the ROI should be known. This has to be wide enough to include normal

breast tissue around the lesion for the comparison of lesion surrounding normal tissues as regard the stiffness. The elasticity image was displayed with 256 colors mapping according to the degree of strain within the region by using a scale from red to green. Then strain image was allowed analysis of the strain ratio values which were calculated. The results were also confirmed by histopathological examination, follow up and MRI mammography.

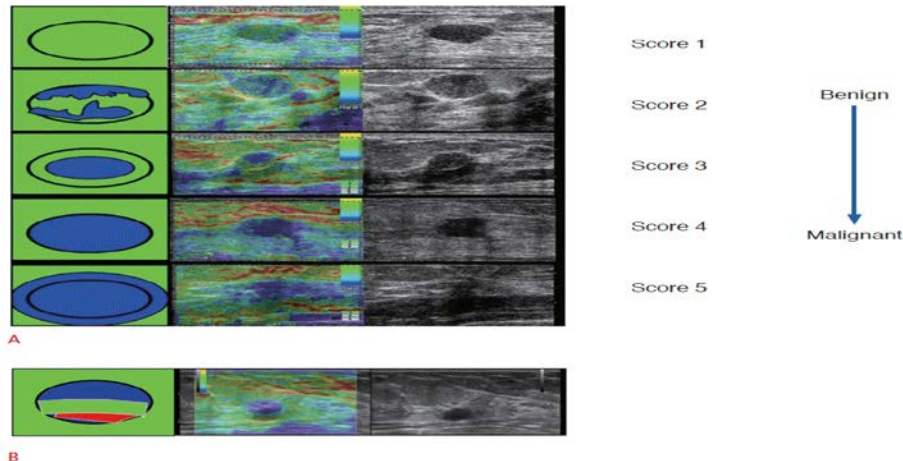
RESULT:

In this study 50 female patients with palpable breast lumps were included having the age group 20 to 70 years with a mean age of 46 years. All patients were evaluated by gray scale ultrasound and sono-elastography examination with multiple different pathological lesions. According to the diagnosis in all the cases the lesions subdivided into 32 benign and 18 malignant lesions according to MRI, histopathological findings and follow up. Ultrasound elastography of breast lesions were done in all the patients’ being classified according to modified Ueno and Ito elasticity score system. Benign lesions which had elastography score as 1, 2, 3 and 4 are follow as 7(21.9%) lesions had elastography score 1, 16 (50%) lesions had elastography score 2, 2(6.3%) lesions had elastography score 3 and 7 (21.9%) lesions had elastography score 4. Whereas malignant breast lesions having elastography score 3, 4 and 5 are as follow: 3(16.7%) lesions had elastography score 3, 12(66.7%) lesions had elastography score 4 and 3(16.7%) lesions had elastography score 5 as shown in table below table 1.

Table 1: Relation between the elastography score and the diagnosis of breast lesions

Elastography score	Total (n=50)		Benign lesion (n = 32)		Malignant lesion (n = 18)		X ²	p
	No	%	No	%	No	%		
1	7	16	7	21.9	0	0.0	7.84	0.00511
2	16	30	16	50.0	0	0.0		
3	5	10	2	6.3	3	16.7		
4	19	38	7	21.9	12	66.7		
5	3	6	0	0.0	3	16.7		

The chi-square statistic is 7.84. The p-value is .00511. The result is significant at $p < 0.05$.



Above figure showing strain elastography images of breast masses. Fig(A). Elasticity scores (Tsukuba score) is five-point scale with increasing probability of malignancy. Score of 1 indicates strain throughout the entire hypoechoic lesion; score 2 shows strain in most of the hypoechoic lesion with some areas of no strain; score 3 shows strain at the periphery of the hypoechoic lesion with sparing of the

center of the lesion; score 4 shows no strain throughout the entire hypoechoic lesion; and score 5 shows no strain throughout the entire hypoechoic lesion or in the surrounding area. Fig(B). An aliasing artifact that appears as a blue-green-red (BGR) pattern which seen in a simple cyst. Note that a color code of red indicates soft and blue indicates hard.

Table 2: Relation between the pathological diagnosis and elastography score

Elastography score	Benign lesion (n = 32)	Malignant lesion (n= 18)	Sensitivity %	Specificity %	PV %	NPV %	Accuracy %
1+2+3	25	3	80	80.95	75.0	85.0	80.56
4+5	7	15					

According to the elastography score ultrasound elastography in breast lesions Sensitivity and specificity as benign lesions should have score 1, 2 and 3 and malignant lesions should take score 4 and 5. In this study 7 lesions out of 32 benign lesions took score 4 and 3 lesions out of 18 malignant lesions had score 3. Therefore, sensitivity of elastography test was 80%, while specificity was 80.95% with PPV 75% and NPV 85% and accuracy 80.56% as shown in above table.

Table 3: Final diagnosis of all breast lesions

Pathological diagnosis	Pathological diagnosis
Fibro adenoma	18
Fibrocystic disease	6
Simple cyst	6
Ductal carcinoma in situ	4
Invasive ductal carcinoma	11
Anaplastic carcinoma	4
Fibrocystic disease with atypia	1

In this study Fibro adenoma, fibrocystic disease and Simple cyst were the most common benign lesions while Invasive ductal carcinoma and Ductal carcinoma in situ was the most common malignant

lesion as shown in above table. In the patients with breast cancer, consideration should be taken that may need the use of other imaging modalities as MRI or may depend upon for follow up in order to verify the newly developed lesion. It is recurrence or post management changes or even a de novo lesion.

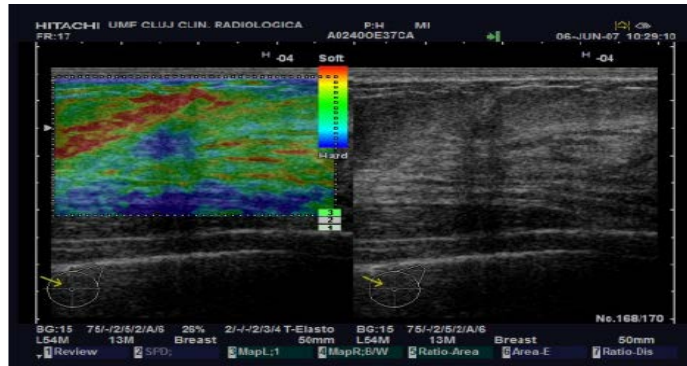


Figure showing USE image of a focal breast lesion: large elastography box showing the soft predominantly red and green aspect of subcutaneous fat (white star) and a more rigid appearance (predominantly blue and green) of the pectoralis muscle (white arrow).

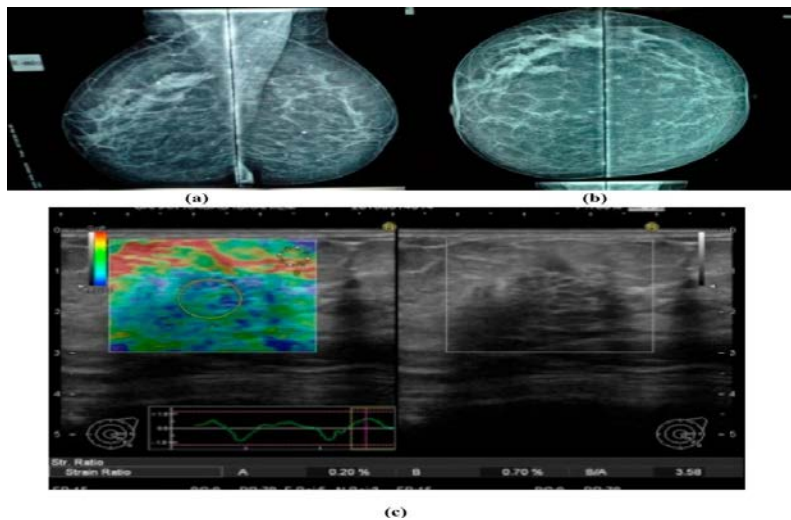


Fig. showing 35 years female with palpable right breast lump (a) Mammogram showed focal asymmetry in the upper quadrant in the right breast. (b) Mammogram showed focal asymmetry in the upper quadrant. (c) US and elastography, showed aggregated dense glandular tissue with score 4 (the lesion was blue color).The final diagnosis was confirmed by core needle biopsy as ductal carcinoma in situ.

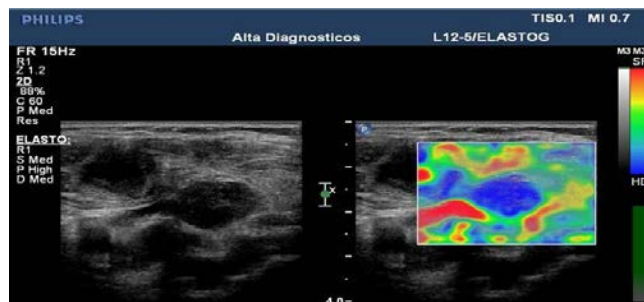

Figure showing B-mode image (left) of a cervical lymph node which shows a hypoechoic rounded lymph node. Elastogram (right) showed that the lymph node is stiffer compared to surrounding tissue suggesting an abnormal lymph node that warrants biopsy.

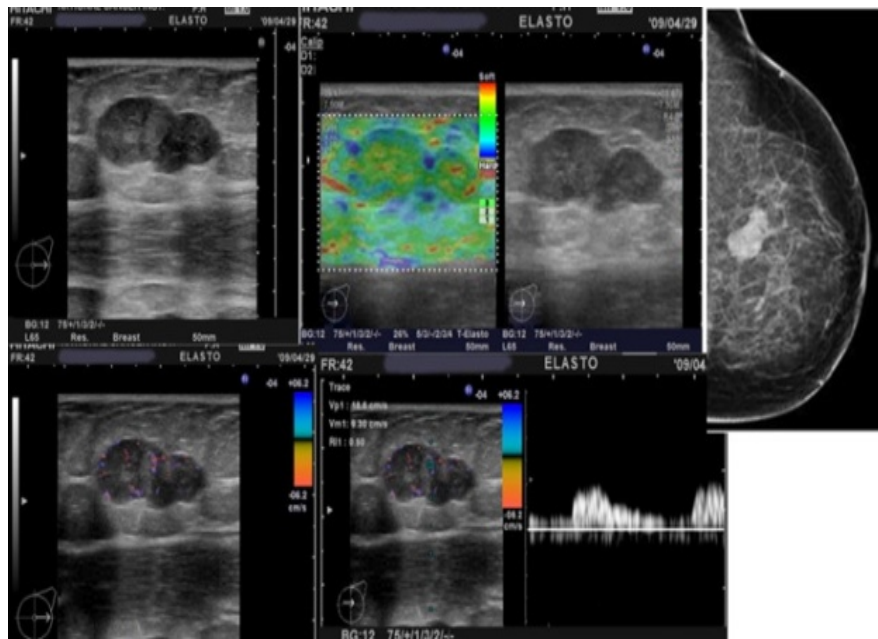


Fig. showing 53 years old woman presented with clinically left breast mass, Mammography showing ACR pattern 3; descriptive criteria include an oval macro-lobulated dense well defined left breast mass. B-mode U/S showed an oval parallel lobulated hypo-echoic focal lesion. Lesion Size: 35 × 18 mm. Doppler Color score: 2 & RI: 0.5 U/S elastography: UE score 2. Final combined (B-mode US, Doppler US & UE) diagnosis shows probably benign. Pathological diagnosis: Invasive duct carcinoma.

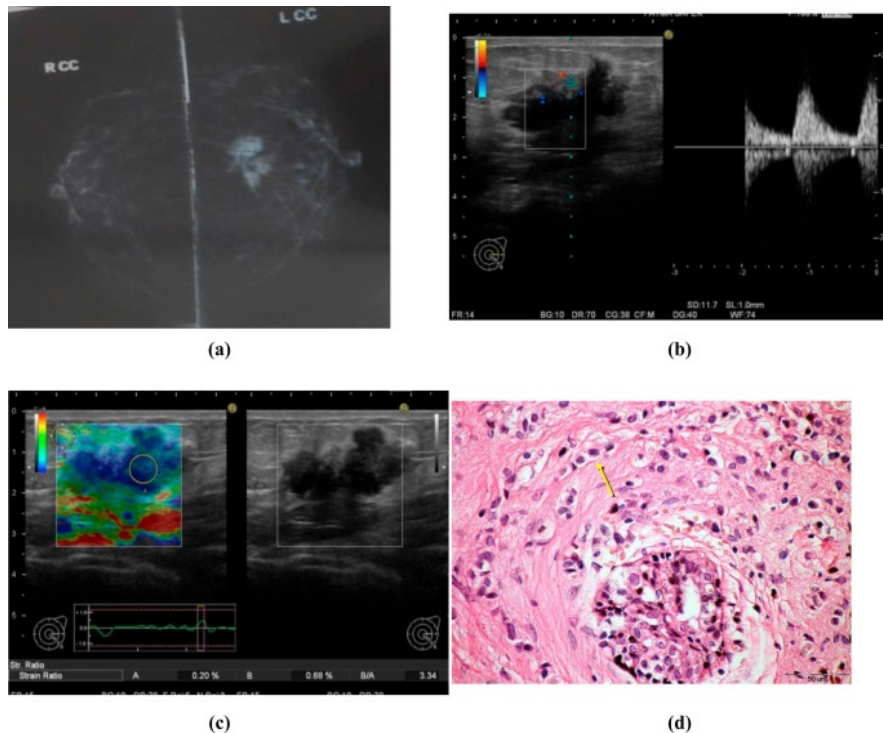


Figure showing 55 years female with palpable left breast lump. (a) Mammogram showed dense opacity with irregular outlines in the inner quadrant from the left breast. (b) Conventional US showed hypoechoic lesion with irregular borders, posterior acoustic shadowing with detected vascularity on color Doppler. (c) elastography of the lesion showed score 4. (d) FNAC of the mass revealed infiltrating ductal carcinoma with small hyperchromatic cells around proliferating ducts.

DISCUSSION:

This study shows high diagnostic relent of using combined diagnostic modalities including US elastography, B-mode US and color Doppler. Such type of diagnostic combination could exclude presence of cancer by specificity rates of about 90%, NPV of 95% and accuracy. Use of non-invasive imaging modalities is an important for diagnosis of breast masses. Ultrasound is the oldest cross-sectional imaging modality which stays for years. Now there is competition with other imaging modalities such as CT, PET and MRI^{20, 21}. The main imaging tool in young females is Sonography which is considered as sensitive modality to detect breast cancers²². In the study of Mansour and Omar et al found that UE can be use as both qualitative and quantitative methods that can improve performance of conventional B-mode ultrasound. its specificity and accuracy also enhance in the diagnosis of questionable (BI-RADS categories 3 and 4) breast lesions²³. According to study of Zhi et al, there is highly significant correlation between the elastogram color distribution and malignant lesions percentage with sensitivity, specificity and accuracy rates of 86.4%, 80.8%, and 83.5%, respectively which were higher than US with AUC = 0.86 which is similar to this study. to confirm the diagnosis of malignant lesions A biopsy is a mandatory process. However, frequency of increased breast biopsies for benign lesions which is considered as another problem due to cost, stress and increased risk of infection and it is still an invasive technique²⁴.

Studied conducted by Garra BS et al 73% of fibroadenomas can be diagnosed different form malignant lesions which depending upon its size, brightness and stiffness in ultrasound and elastography examination which is similar to this study as well as study of GM et al^{25, 26}. Some breast cancer as benign features (score 1–3) may display on elasticity imaging such as inflammatory carcinoma, non-differentiated DCI, hyper cellular, necrotic or pseudo cystic malignant lesion deep small neoplastic nodules and large cancers over 2.5cm in diameter²⁷. For the evaluation of post- operative changes,

diffuse lesions or large ones Elastography is not indicated which exceeds the probe length or its field of view²⁸

CONCLUSION:

For the improvement in diagnostic test with high sensitivity and specificity UE could be used and also improved the diagnostic yield of other tests when used in combination. For examination of suspected breast cancer elastography should be used as an adjunct to the conventional B-mode examination. Elastography also provided other characterization of breast lesions which improve the specificity for low suspicion lesions achieved at conventional US.

REFERENCES:

1. Levine M, Moutquin JM, Walton R, Feightner J. Canadian task force on preventive health care and the Canadian Breast Cancer Initiative's Steering Committee on Clinical Practice. Chemoprevention of breast cancer. A joint guideline from the Canadian Task Force on Preventive Health Care and the Canadian Breast Cancer Initiative's Steering Committee on Clinical Practice Guidelines for the Care and Treatment of Breast Cancer. CMAJ 2001;164(12):1681–90.
2. Nelson HD, Smith ME, Griffin JC, Fu R. Use of medications to reduce risk for primary breast cancer: a systematic review for the U.S. Preventive Services Task Force. Ann Intern Med 2013;158(8):604–14.
3. Kinsinger LS, Harris R, Woolf SH, Sox HC, Lohr KN. Chemoprevention of breast cancer: a summary of the evidence for the U.S. Preventive Services Task Force. Ann Intern Med 2002;137(1):59–69.
4. Thomsen A, Kolesar JM. Chemoprevention of breast cancer. Am J Health Syst Pharm 2008;65(23):2221–8.
5. Tardivon A, El Khoury C, Thibault F, Wyler A, Barreau B, Neuenschwander S. Elastasonography of the breast: prospective study of 122 lesions. J Radiol 2007;88:657–62

6. Céspedes I, Ophir J, Ponnekanti H et al. Elastography: elasticity imaging using ultrasound with application to muscle and breast in vivo. *Ultrason Imaging* 1993; 15: 73–88
7. Garra BS, Cespedes EI, Ophir J et al. Elastography of breast lesions: initial clinical results. *Radiology* 1997; 202: 79–86
8. Konofagou E, Ophir J. A new elastography method for estimation and imaging of lateral displacements, lateral strains, corrected axial strains and Poisson's ratios in tissues. *Ultrasound Med Biol* 1998; 24: 1183–1199
9. Krouskop TA, Wheeler TM, Kallel F, Garra BS, Hall T. Elastic moduli of breast and prostate tissues under compression. *Ultrason Imaging* 1998;20:260-74.
10. Ophir J, Céspedes I, Ponnekanti H, Yazdi Y, Li X. Elastography: A quantitative method for imaging the elasticity of biological tissues. *Ultrason Imaging* 1991;13:111-34.
11. Klauser AS, Faschingbauer R, Jaschke WR. Is sonoelastography of value in assessing tendons? *Semin Musculoskelet Radiol* 2010;14:323-33.
12. Itoh A, Ueno E, Tohno E, Kamma H, Takahashi H, Shiina T, et al. Breast disease: Clinical application of US elastography for diagnosis. *Radiology* 2006;239:341-50.
13. Hoskins, P.R. Principles of ultrasound elastography. *Ultrasound* 2012, 20, 8–15.
14. El Saghir NS. Responding to the challenges of breast cancer in Egypt and other Arab countries. *J Egypt Natl Canc Inst* 2008;20(4):309–12.
15. Houssami N, Lord SJ, Ciatto S. Breast cancer screening: emerging role of new imaging techniques as adjuncts to mammography. *Med J Aust* 2009;190(9):493–7.
16. Parkin DM, Fernandez LM. Use of statistics to assess the global burden of breast cancer. *Breast J* 2006;12(Suppl. 1):S70–80
17. Omar S, Khaled H, Gaafar R, Zekry AR, Eissa S, El-Khatib O. Breast cancer in Egypt: a review of disease presentation and detection strategies. *East Mediterr Health J* 2003;9:448–63
18. Ophir J, Alam SK, Garra B, Kallel F, Konofagou E, Krouskop T, et al. Elastography: ultrasonic estimation and imaging of the elastic properties of tissues. *Proc Inst Mech Eng H* 1999;213:203–33
19. Itoh A, Ueno E, Tohno E, Kamma H, Takahashi H, Shiina T, et al. Breast disease: clinical application of US elastography for diagnosis. *Radiology* 2006;239 (2):341–50
20. Sadigh G, Carlos RC, Neal CH, Wojcinski S, Dwamena BA. Impact of breast mass size on accuracy of ultrasound elastography vs. conventional B-mode ultrasound: a meta-analysis of individual participants. *J Eur Radiol* 2013;23 (4):1006–14
21. Gheonea IA, Stoica Z, Bondari S. Differential diagnosis of breast lesions using ultrasound elastography. *Indian J Radiol Imaging* 2011;21(4):301–5
22. Akhtar MS, Mansoor T, Basari R, Ahmed I. Diagnoses of breast masses with ultrasonography and elastography: a comparative study. *Clin Cancer Invest J* 2013;2(4):311–8
23. Mansour SM, Omar OS. Elastography ultrasound and questionable breast lesions: does it count? *Eur J Radiol* 2012;81(11):3234–44.
24. Costantini M, Belli P, Lombardi R, Franceschini G, Mulè A, Bonomo L. Characterization of solid breast masses: use of the sonographic breast imaging reporting and data system lexicon. *J Ultrasound Med* 2006;25:649–59
25. Garra BS, Cespedes EI, Ophir J, Spratt SR, Zurbier RA, Magnant CM, et al. Elastography of breast lesions: initial clinical results. *Radiology* 1997;202 (1):79–86
26. Giuseppetti GM, Martegani A, Di Cioccio B, Baldassarre S. Elastasonography in the

diagnosis of the nodular breast lesions:
preliminary report. Radiol Med
2005;110(1-2):69-76

27. Insana MF, Pellot-Barakat C, Sridhar M, Lindfors KK. Viscoelastic imaging of breast tumor microenvironment with ultrasound. J Mammary Gland Biol Neoplasia 2004;9(4):393-404
28. Cohn M. Strain ratio adds objectivity, improves sensitivity in ultrasound elastography. 2010. UBM Medica LLC, Diagnostic imaging.com.