



ROLE OF SONOGRAPHIC IMAGING AND SPERM COUNT IN MALE INFERTILITY

Dr. Jayesh B. Solanki¹, Dr. Deepak S. Howale²

¹Senior Consultant Dept. of Radiology Shri Vinoba Bhave Civil Hospital, Silvassa

²Dean Govt. Medical College and Shri Vinoba Bhave Civil Hospital, Silvassa.

Abstract:

Male infertility is more importance with male factors which implicated as the cause to half of the infertile couples. Besides routine investigations ultra sonography of trans rectal and scrotal was performed to detect testicular and post-testicular etiology or abnormality. Infertility is considered one of the main public health issues. Failure to fulfill to get pregnancy during 1 year of frequent, unprotected intercourse is known as infertility. Male factor is responsible in half of the cases, however, unexplained infertility are still classified as 15% of the cases. In the general population including people with fertility problems, about 84% of females would conceive within 1 year of regular unprotected sexual intercourse which rises 93% to cumulatively after 3 years. The male factor involved in 40% - 50% of infertility cases. Other causes like obstruction to spermatic ducts, varicocele, post radiation or orchidectomy are less common causes of oligospermia. About 60-65 % cases of male infertility Sperm factor is responsible. Therefore semen analysis and physical examination a scrotal ultrasonography (US) may help to demonstrate obstruction or testicular dysgenesis, due to its noninvasiveness, safety and absence of exposure to radiation US is the first-line imaging modality to evaluate male genital tract. **Aim:** The aim of this study is to evaluate the causes of infertility in men with obstruction of the seminal tract, ultrasonography (medical imaging investigations) and also determine the critical testicular volume necessary for adequate sperm production and suggests guidelines for referral to infertility specialists. **Material and method:** This is the prospective cross- section study which is carried out on 50 patients between the age group 27 to 48 years old male visiting the ultrasound section of SVBCH Silvassa Hospital in the Department of Radiology in a period of one year. All the patients were referred to the Department of Radiology for scrotal ultrasound from the urology clinic. All scrotal ultrasound scans were done using a Mindray DC-8 diagnostic ultrasound system with a 7.5MHz transducer in the presence of a male chaperone. Over both scrotal sacs coupling gel was applied and examination was done in both longitudinal and transverse planes. The semen sample was collected after 3-4 days abstinence by masturbation and modified 'masturbation'. The semen sample was then processed and analyzed in the laboratory. Subjects were educated on method of collection. The semen parameters analyzed included semen volume, sperm concentration and total sperm count. **Conclusion:** There is essential to investigation of infertile male patients in order to identify potentially treatable infertility causes and guide therapy. Therefore small testicular size is associated with decreased sperm count as well as the testicular size increases the sperm count also increases. Scrotal USG is an important investigation in evaluation subclinical varicocele for early diagnosis and management of male infertility.

Initial analysis of male infertility can be utilized by assessing the testicular size, by indirectly assessing the possible sperm count.

Key words: Male infertility, ultrasonography, sperm count, varicocele and Testicular volume

INTRODUCTION

Infertility is considered one of the main public health issues. Failure to fulfill to get pregnancy during 1 year of frequent, unprotected intercourse is known as infertilityⁱ. This problem is suffering one in six couples attempting to conceive child and seek treatment for infertility. Male factor is responsible in half of the cases, however, unexplained infertility are still classified as 15% of the casesⁱⁱ. In the general population including people with fertility problems, about 84% of females would conceive within 1 year of regular unprotected sexual intercourse which rises 93% to cumulatively after 3 years^{iii,iv}. The male factor involved in 40% - 50% of infertility cases. The most common type of male infertility is idiopathic infertility that is characterized by the presence of one or more abnormal semen parameters like abnormal shape of sperms, decreased sperm count, decreased sperm count with no identifiable cause^v. Other causes like obstruction to spermatic ducts, varicocele, post radiation or orchidectomy are less common causes of oligospermia. About 60-65 % cases of male infertility Sperm factor is responsible^{vi}. If the female partner is older than 35 years or instigated earlier if there is a high clinical suspicion of infertility; most couples conceive within a year, assessment of the presenting couple is usually initiated after 12 months. A careful history and physical examination of partner can suggest a single or more usually multifactorial aetiology and directs further investigation^{vii}. In addition to semen analysis and physical examination a scrotal ultrasonography (US) may help to demonstrate obstruction or testicular dysgenesis^{viii}. Due to its noninvasiveness, safety and absence of exposure to radiation US is the first-line imaging modality to evaluate male genital tract^{ix}. US is limited to the functional analysis of testicular tissue. Recent technical advances in US applications and post-processing developments have provided new insights for the structural and functional evaluation of testicular

tissue^x. Ultrasound examinations are the common investigations for scrotum and semen analysis done in evaluating male sub fertility. Ultrasound is a very useful modality for assessing the testicular size^{xi}. A major cause contributing for male infertility is an atrophic testes which is closely associated with oligospermia^{xii,xiii}. The first line investigation in evaluation of male infertility is Semen analysis of male partner for infertile marriages. The sperm count per ejaculation after abstinence of 3-4 days is a better indicator of male fertility^{xiv,xv}. The aim of this study is to evaluate the causes of infertility in men with obstruction of the seminal tract, ultrasonography (medical imaging investigations) and also determine the critical testicular volume necessary for adequate sperm production and suggests guidelines for referral to infertility specialists.

MATERIAL AND METHOD:

This is the prospective cross- section study which is carried out on 50 patients between the age group 27 to 48 years old male visiting the ultrasound section of Shri Vinoba Bhawe Civil Hospital, Silvassa Hospital in the Department of Radiology in a period of one year. All the patients were referred to the Department of Radiology for scrotal ultrasound from the urology clinic. In this study patients with a history of diabetes mellitus, hypertension and renal disease were excluded.

All scrotal ultrasound scans were done using a Mindray DC-8 diagnostic ultrasound system with a 7.5MHz transducer in the presence of a male chaperone. Patients were explaining before examination that was then placed in a supine position. Underwear and trousers were placed at the mid-thigh level. The scrotums were support via a folded towel positioned between the patient's legs. The penis was then placed over the patient's suprapubic region and covered with another towel. Over both scrotal sacs coupling gel was applied and examination was done in both longitudinal and transverse planes.

The formula $\text{Length} \times \text{Width} \times \text{Height} \times 0.71$ was used to obtain the testicular volume^{xvi}. Three separate testicular length, width and height were

measured using electronic calipers, excluding the epididymis. As shown in figure below.

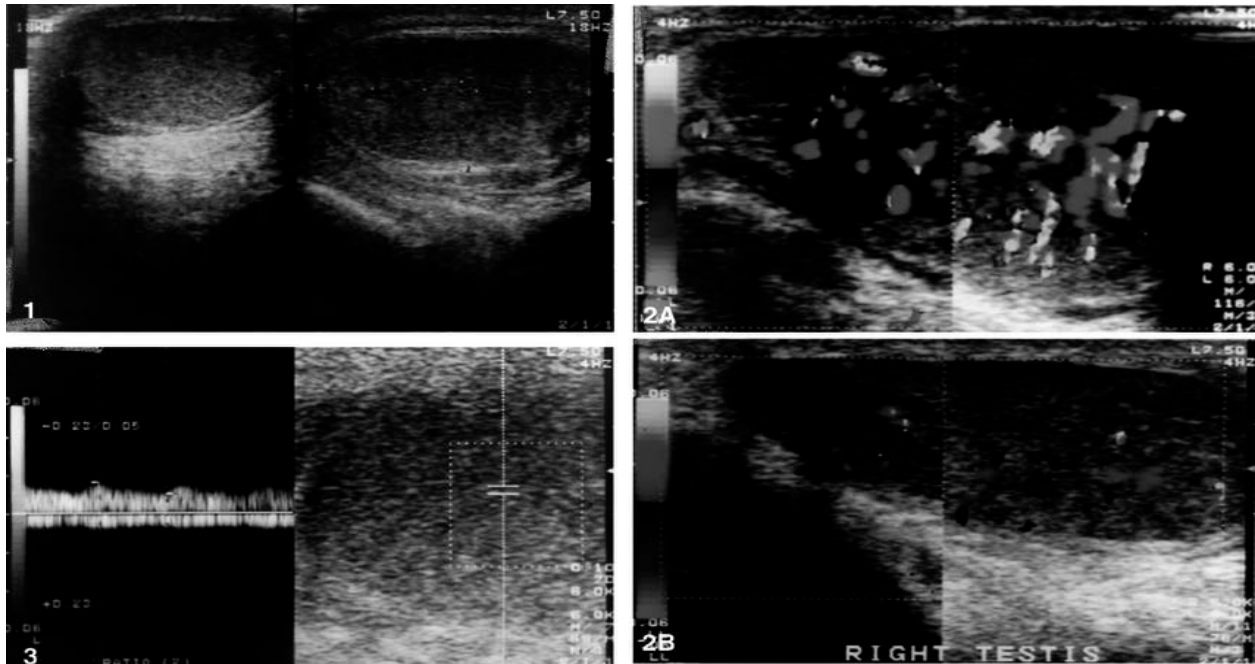


Figure 1: showing sonogram of longitudinal testicular enlargement and in bilateral orchitis case.

Figure 2A: showing vascularity increased in number and concentration in testes and epididymis in all cases in dropper US examination.

Figure 2B: showing US and color Doppler US findings began to normalize in the third day of the therapy

Figure 3: showing right intratesticular arteries were less than 0.5 (between 0.33– 0.48) in 10 cases and 0.56 in one case (mean 0.43)

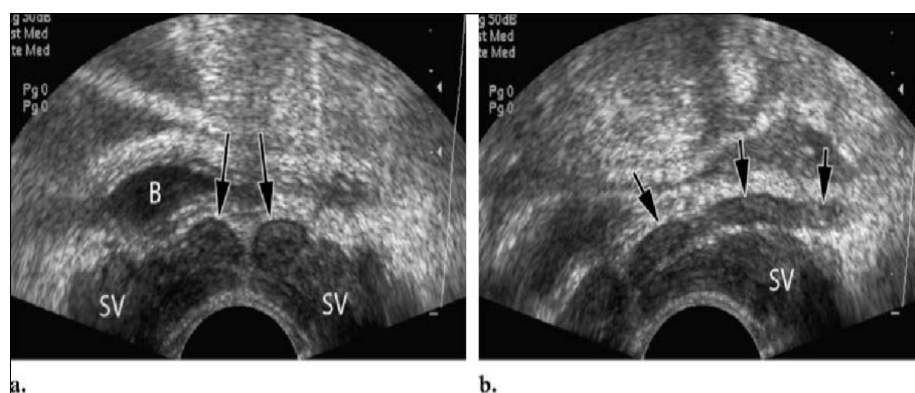


Figure: Ultrasonographic (US) of the SVs and vasa deferentia. (a) US of Transverse image from transrectal showing symmetric SVs and more medially located vasa deferentia (arrows) obtained above the prostate. (b) US of Oblique from transrectal shows the left VD (arrows) joining the duct of the SV. The semen sample was collected after 3-4 days abstinence by masturbation and modified 'masturbation'. In modified masturbation, the wife of the subject did the 'masturbation' in a dedicated room within the hospital premises. The semen sample was then processed and analyzed in the laboratory. Subjects were educated on method of collection. The semen parameters analyzed included semen volume, sperm

concentration and total sperm count. Normal semen volume was considered as a volume of ≥ 2 ml. Normal sperm concentration was considered as a concentration of $\geq 15 \times 10^6$ cells/ml. Abnormal sperm parameters were considered as follows; aspermia - no ejaculate, azoospermia - no spermatozoa, oligospermia - $< 15 \times 10^6$ cells/ml, severe oligospermia - $< 5 \times 10^6$ cells/ml^{xvii}.

RESULTS AND OBSERVATIONS:

Table 1: Age distribution of subjects

Age (years)	Frequency	Percent (%)
27-32	6	12
33-38	11	22
39-44	24	48
45-50	9	18
Total	50	100

A total number of 50 patients were evaluated with B-mode ultrasound during the study period. Their ages ranged from 27 - 48 years with a mean age of 39.16 ± 4.7 years. The modal age group was 36 - 40 years (39 or 39%) while the age group with the lowest frequency was 27 years (6 or 12%) as above table.

Table 2: Showing demographic data and clinical characteristics of individuals.

Number of patients (n)	50	P value
Mean age (years)	39.16 ± 4.7	0.444
Mean testicular volume (mL)	19.4 ± 4.9	0.023 *
Mean strain values	5.3 ± 2.5	0.657
Number of spermatozoa (nx10 ⁶ /mL)	61.2 ± 30.2	<0.001 *
Morphology (%)	5.1 ± 1.6	<0.001 *
Mean number of total motile sperm (%)	37.6 ± 3.7	<0.001*

*statistical significance

DISCUSSION:

In the world Infertility is a significant health concern increasing in incidence. About 40-50% of the infertile couples the male factor is considered to be the cause of infertility. The causes of male infertility are broadly differentiated into non-correctable or treatable causes. Due to testicular atrophy the decreased sperm count cannot be corrected whereas oligospermia caused by obstruction to the transport of sperm at spermatic duct or ejaculatory duct are possibly correctable¹². Speroff L et al have found that the cause of infertility in about 65 % cases is sperm factor of male infertility. Idiopathic cause is the common

reason of oligospermia, followed by varicocele. According to study of Sabanegh E et al has found in different studies that a small sized testis is associated with low fertility. Different studies have shown that there is a significant correlation between testicular volume obtained by ultrasound and testicular function^{xviii}. According to Tijani et al there was a statistically significant positive correlation between testicular volume and total sperm count which is similar to this study.

Another study carried out by Sharath et al also showed a significant positive correlation between testicular volume and sperm count ($r=0.501$ p <0.0001) as well a higher MTV for the control population compared to the infertile population^{xix}.

Various imaging studies used for subclinical varicocele are scrotal USG, venography, thermography, and radionuclide scrotal scanning^{xx}. According to study conducted by Gonda et al in 95% patients showed that sonography was positive for subclinical varicocele, whereas in only 55% nuclear scanning was considered positive. The reproducibility and noninvasiveness of scrotal USG have led to its increased use in the diagnosis of varicocele. Detection of subclinical varicocele is important for the decision-making process and further investigated by USG^{xxi}. Treatment of cases with subclinical varicocele is controversial whereas in infertile patients partial beneficial effect on sperm parameters was shown with subclinical varicocele in randomized controlled study^{xxii}. For achievement for favorable pregnancy rates patients treated and emphasizes the importance of making the diagnosis of subclinical patient²¹. Long-term follow-up for patients should be carried out to know the progress of this varicocele. By treating of subclinical varicoceles will improve seminogram parameters and fertility potential needs to be investigated.

CONCLUSION:

There is essential to investigation of infertile male patients in order to identify potentially treatable infertility causes and guide therapy. Therefore small testicular size is associated with decreased sperm count as well as the testicular size increases the sperm count also increases. Scrotal USG is an important investigation in evaluation subclinical varicocele for early diagnosis and management of male infertility. Initial analysis of male infertility can be utilized by assessing the testicular size, by indirectly assessing the possible sperm count.

REFERENCES:

1. Guttmacher AF. Factors affecting normal expectancy of conception. *J Am Med Assoc* 1956;161:855–60.
2. WHO, WHO Manual for the Standardized Investigation and Diagnosis of the Infertile Couple. 2000, Cambridge University Press: Cambridge.
3. te Velde ER, Eijkemans R, Habbema HDF. Variation in couple fecundity and time to pregnancy, an essential concept in human reproduction. *Lancet* 2000;355:1928–9.
4. Bongaarts J. A method for the estimation of fecundability. *Demography* 1975;12:645–60.
5. Speroff L, Glass RH, Kase NG. *Clinical Gynecologic Endocrinology and Infertility*. 6th Ed. Baltimore USA: Lippincott Williams and Wilkins; 1999. Infertility; pp. 201–246.
6. Baker HW. Male infertility. *Endocrinol Metab Clin North Am*. 1994; 23: 783–793.
7. Jose-Miller AB, Boyden JW, Frey KA. Infertility. *Am Fam Physician* 2007;75:849–56.
8. Ammar T, Sidhu PS, Wilkins CJ. Male infertility: the role of imaging in diagnosis and management. *Br J Radiol* 2012;85:S59–68.
9. Jungwirth A, Giwercman A, Tournaye H, Diemer T, Kopa Z, Dohle G, et al. European Association of Urology Working Group on Male Infertility. *Eur Urol* 2012;62:324–32.
10. Schurich M, Aigner F, Frauscher F, Pallwein L. The role of ultrasound in assessment of male fertility. *Eur J Obstet Gynecol Reprod Biol* 2009;144(Suppl 1):S192–8.
11. ^{xi} Fuse H, Takahara M, Ishii H, Sumiya H, Shimazaki J. Measurement of testicular volume by ultrasonography. *Int J Androl* 1990, 13(4): 267–72
12. Mukund Joshi. Role of ultrasound in assessment of male infertility. *Biomed Imaging Interv J* 2007; 3 (1): e12–47.
13. B Mirochnik, P Bhargava, M K Dighe, N Kanth. Ultrasound evaluation of scrotal pathology. *Radiologic Clinics of North America* 2012; 50 (2): 317–332.
14. The sperm count per ejaculation after abstinence of 3-4 days is a better indicator of male fertility
15. Patrick J Taylor, Renée H Martin. Semen Analysis in the Investigation of Infertility. *Can Fam Physician*. Jan 1981; 27: 113–116
16. Spitz A, Kim ED, Lipshultz LI. Contemporary approach to male infertility

-
- evaluation. *Obstet Gynecol Clin North Am.* 2000;27:487-516.
17. WHO laboratory manual for the examination and processing of human semen. World Health Organization, Department of Reproductive Health and Research. 5th Edition 2010, WHO Press. Switzerland. 2010;7-113.
 18. Sobowale OB, Akiwumi O. Testicular volume and seminal fluid profile in fertile and infertile males in Ilorin, Nigeria. *Int J Gynaecol Obstet.* 1989;28(2):155-161.
 19. Sharath KC, Najafi M, Vineeth VS, Malini SS. Assessment of testicular volume in correlation with spermiogram of infertile males in south India. *Adv Stud Biol.* 2013; 5(7):327-335.
 20. World Health Organization. Comparison among different methods for the diagnosis of varicocele. *Fertil Steril* 1985;43: 575–82.
 21. Gonda RL, Karo JJ, Forte RA, O'Donnell KT. Diagnosis of subclinical varicocele in infertility. *AJR Am J Roentgenol* 1987;148:71–5.
 22. Yamamoto M, Hibi H, Tsuji Y, Miyake K. The effect of varicocele ligation on oocyte fertilization and pregnancy after failure of fertilization in in vitro fertilisation embryo transfer. *Hinyokika Kiyo* 1994;40:683–7.