



A Case Series

**William Syndrome Associated with Hypertrophic Cardiomyopathy
and Severe Left Ventricular Outflow Obstruction: A Rare Case
Report**

Akhil Mehrotra¹, Ujala Shakya², Mohammed Shaban³, Shubham Kacker⁴

¹ Chief, Pediatric and Adult Cardiology, Prakash Heart Station, Nirala Nagar, Lucknow, UP, India.

^{2,3} Cardiac Technician, Prakash Heart Station, Nirala Nagar, Lucknow, UP, India.

⁴ Lead PMO, Tech Mahindra, New Delhi, India.

Received: 25-05-2023 / Revised: 05-06-2023 / Accepted: 25-06-2023

Conflicts of Interest: Nil

Corresponding author: Dr. Akhil Mehrotra

DOI: <https://doi.org/10.32553/ijmsdr.v7i4.985>

Abstract:

Williams syndrome (WS), also referred to as Williams-Beuren syndrome, is a rare complex congenital developmental multisystem disorder, occurring in 1 per 20,000 live births. It is characterized by congenital heart defects (CHD), skeletal, renal anomalies, cognitive disorder, social personality disorder and notably dysmorphic Elfin-like facies. Supravalvular aortic stenosis is the most frequent cardiovascular abnormality in WS children. WS occurs as the result of a deletion of approximately 1.5-1.8 Mb on chromosome 7q11.23. The deletion is almost always *de novo*, however familial cases have been reported. Genetic study is usually required for a definitive diagnosis, but genetic testing is often unavailable in the developing countries and the combination of a typical clinical phenotype and echocardiographic profile helps to confirm the diagnosis. The prevalence of hypertrophic cardiomyopathy (HCM) is about 0.05 to 0.2% of general population and is extremely scarce in association with WS. The occurrence of HCM is a significant cause of sudden cardiac death (SCD) in any age group and a cause of heart failure. We are reporting an extraordinary case report of Williams's syndrome with HCM complicated by severe left ventricular outflow obstruction (LVOT) in a 5 year old male child.

Keywords: Williams Syndrome, Hypertrophic Cardiomyopathy, Elfin Facies, LVOT obstruction, SAM, SCD.

Introduction

WS is a rare familial multisystem disorder that occurs in 1 per 20,000 live birth. It is characterized by myriads of deformities including congenital heart defects, neonatal

hypercalcaemia, skeletal, renal anomalies, cognitive disorder, social personality disorder and dysmorphic facies. [1] (Figure 1).

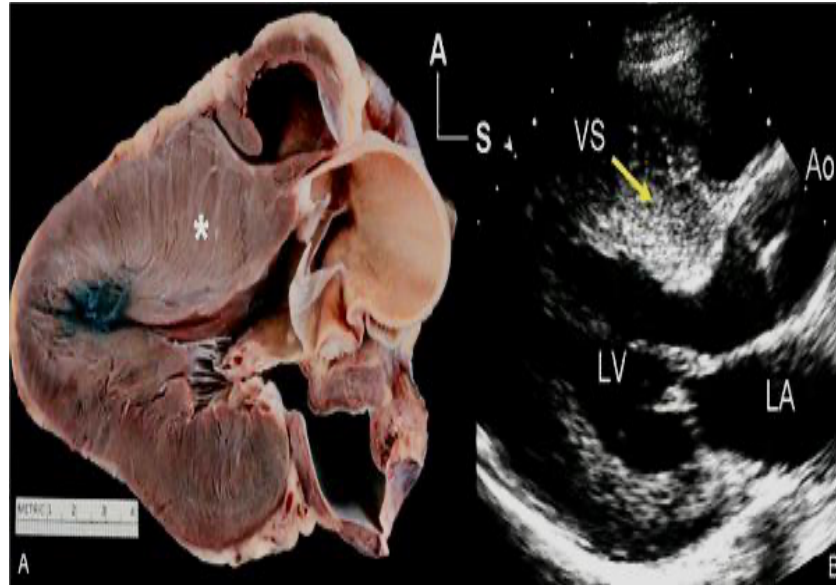


Figure 1: Long-axis anatomy typical of hypertrophic cardiomyopathy. A: Anatomic specimen shows a tremendous increase in left ventricular wall thickness, but the increase in myocardial mass is most prominently displayed in the ventricular septum (asterisk). B: Echocardiographic image displays similar anatomy. The increase in myocardial thickness is less prominent than in the anatomic example, but the basal septum (yellow arrow) is still asymmetrically thickened relative to the posterior left ventricular wall. A, anterior; Ao, aorta; LA, left atrium; LV, left ventricle; S, superior; VS, ventricular septum.

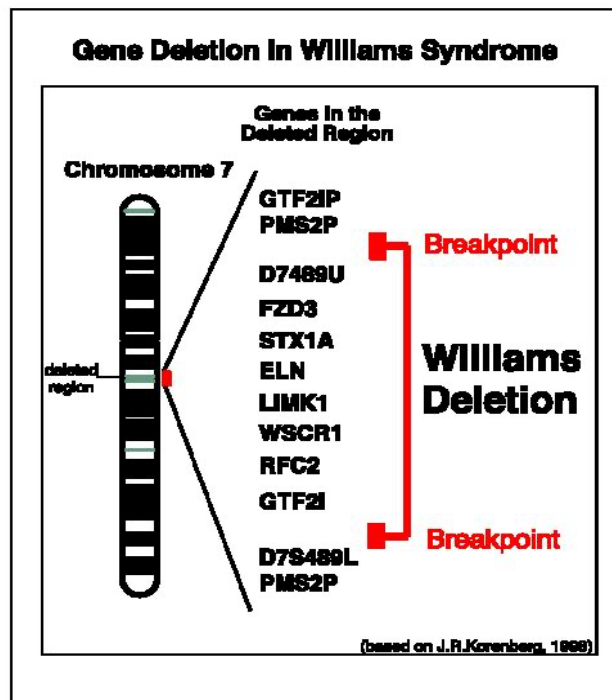


Figure 2: Williams Syndrome is caused by the deletion of one copy of a small set of genes on chromosome 7, band 7 qll23.

The neurocognitive profile of William's syndrome most commonly includes mild mental retardation. Cognitive strengths and weaknesses relative to other patients with mental retardation consists of relatively good auditory rote memory but extreme difficulty with visuospatial construction tasks [2]. Most of the patients with WS have CHDs, which typically includes supravalvular aortic stenosis and/or supravalvular pulmonary stenosis [3, 4]. Patients with WS may commonly develop hypertension either because of renal artery stenosis or COA or other undefined etiologies [3].

Approximately 90% of WS have a deletion at chromosome 7q11.23, which can be detected by FISH (fluorescent in situ hybridization) (Figure 2).

The genes mapping to this region have been defined and include the elastin gene. In isolated supravalvular aortic stenosis [5,6] association of deletion of the elastin gene in patients with WS is thought to account for the cardiovascular phenotype [7].

HCM coexisting with WS is extremely rare. In a Finnish study of 75 patients with WS [4], only 2 infants were diagnosed with HCM. Another study of Bruno et al [8], similarly, found the occurrence of HCM was infrequent in their patients. Interestingly, Figueroa et al [9] compared their findings of cardiopathies in WS syndrome with others around the world (Figure 3) and HCM incidence was sparsely reported by all the worldwide studies [10-13].

Figure 3: Cardiopathies in WS syndrome: Experience at National Institute of Pediatrics compared with others around the world.

Cardiopathy	Helsinki ⁽⁴⁾ {n=44}	Mexico ⁽⁹⁾ {n=32}	Salt Lake City ⁽¹⁰⁾ {n=42}	Seoul ⁽¹¹⁾ {n=26}	Madrid ⁽¹²⁾ {n=70}	Toronto ⁽¹⁶⁾ {n=49}
SAoS	21	18	27	6	49	28
PABS	6	3	10	2	4	8
SAoS+PABS	11	4	0	18	10	11
CoA	0	2	0	0	4	1
Aortic stenosis	2	2	0	0	0	0
VSD	0	1	5	0	0	0
PDA	0	1	0	0	0	0
BAo	0	1	0	0	0	0
Other**	4	0	0	0	3	1

BAo = bicuspid aortic valve; CoA = coarctation of the aorta; PABS = pulmonary artery branch stenosis; PDA = patent ductus arteriosus; SAoS = supravalvular aortic stenosis; VSD = ventricular septal defect
 ** Atrial septal defect, cardiomyopathy, mitral valve prolapse, right ventricular hypertrophy, tetralogy of Fallot

Case Report

A five-year male child presented to us for evaluation of a heart murmur. The parents enumerated the details of the patient and according to them, the child was asymptomatic since birth. On a routine check-up for a minor ailment, he was detected to be having a heart

murmur. On clinical examination, the child was thin-built and healthy looking. The weight was 15 kg, height 60 cm, Pulse rate 76/min, respiratory rate 15/min, BP 80/50 right upper limb and SPO₂ of 99% at room air. Distinctive “Eflin-like” facies was evident (Figure 4), with the presence of:

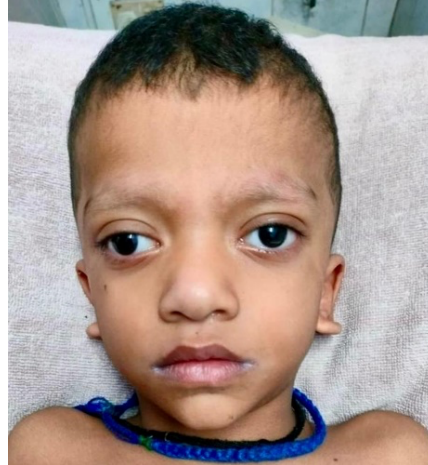

Figure 4: Typical Elfin facies: wide forehead, bilateral epicanthal folds, wide set eyes, sunken bridge of nose, wide nostrils, upturned nose, full cheeks, pointed chin, dysmorphic external ears

- I. Prominent wide forehead
- II. Full cheeks
- III. Sunken nasal bridge
- IV. iv. Long upper lip length (philtrum)
- V. Upturned nose
- VI. Small chin
- VII. Wide set eyes
- VIII. viii. Bilateral dysmorphic ears
- IX. Bilateral epicanthal folds
- X. wide nostrils
- XI. Thick Lips

Besides the presence of conspicuous facies, amongst the musculo-skeletal anomalies, only pectus excavatum deformity of the chest was detected.

On cardiovascular examination, a Grade 3/6 ejection murmur was audible over the precordium best heard in the left second intercostal space, adjacent to the sternal edge. No radiation was detected in the carotids. All the peripheral arteries were normal and there was no radio-femoral delay.

ECG showed (Figure 5) rS complexes from V1-V6, extreme left axis deviation with normal sinus rhythm. X-ray Chest PA view (Figure 6) demonstrated mild cardiomegaly with normal pulmonary blood flow. Pathological reports were unremarkable.

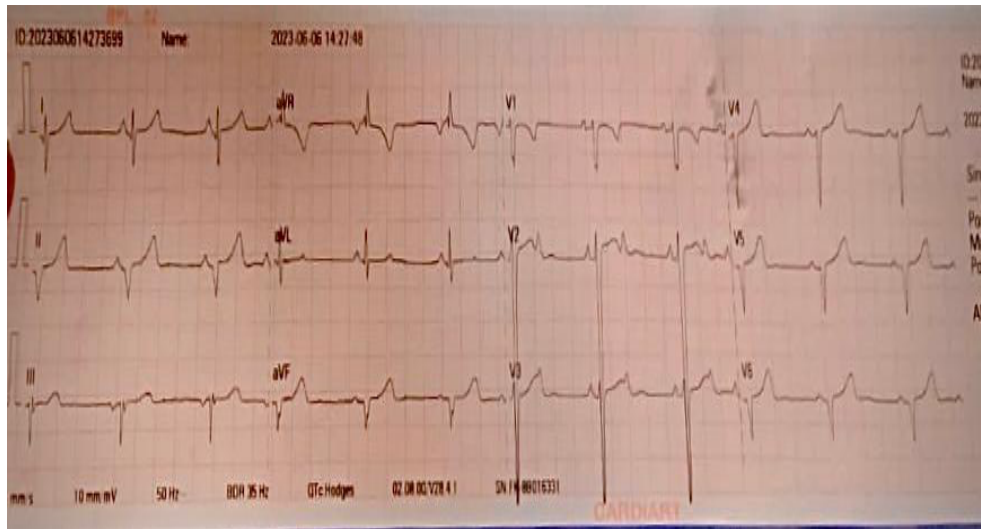


Figure 5: Resting ECG: There is presence of rS complexes in precordial leads V1-V6, extreme left axis deviation, normal sinus rhythm.

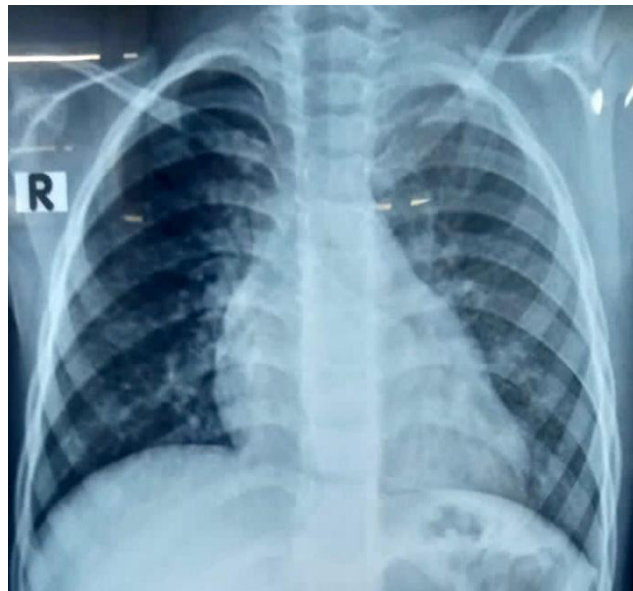


Figure 6: X-ray Chest PA - There is presence of cardiomegaly with normal pulmonary blood flow.

Trans-thoracic echocardiography (TTE)

TTE was performed by the author in the supine and left lateral decubitus positions. Imaging was done from the subcostal, parasternal long axis (LX), parasternal short axis (SX), apical 4-chamber (4CH), apical 5-chamber (SCH) and suprasternal views. There was levocardia, situs solitus, atrioventricular concordance, ventriculo-arterial concordance, concordant-d

bulboventricular loop, normally related great arteries and left aortic arch. Systemic and pulmonary venous drainage was normal.

In the LX views (Figure 7) asymmetrical septal hypotrophy is visualized with marked thickness of basal and mid ventricular septum (Basal septum(D) 11.7 mm, Mid septum (D) 11.9 mm, Distal apical septum(D) 7.9 mm and left ventricular posterior wall(D) 5.2 mm,).

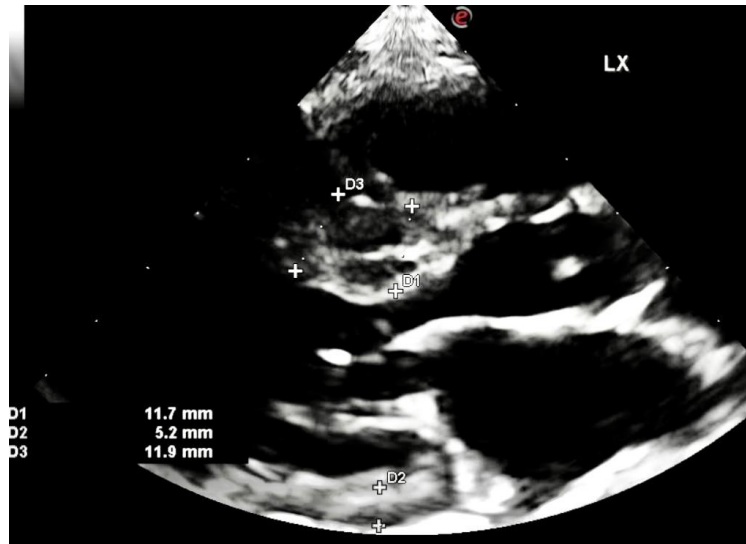


Figure 7: Parasternal LX View - There is presence of remarkable thickness of proximal ventricular septum

The interventricular septum and left ventricular posterior wall ratio was 2.2:1, consistent with hypertrophic cardiomyopathy. M-mode echocardiography analysis at the level of the tip of mitral valve demonstrated a classic systolic anterior motion (SAM) of the anterior mitral leaflet causing a severe LVOT obstruction (Figure 8).

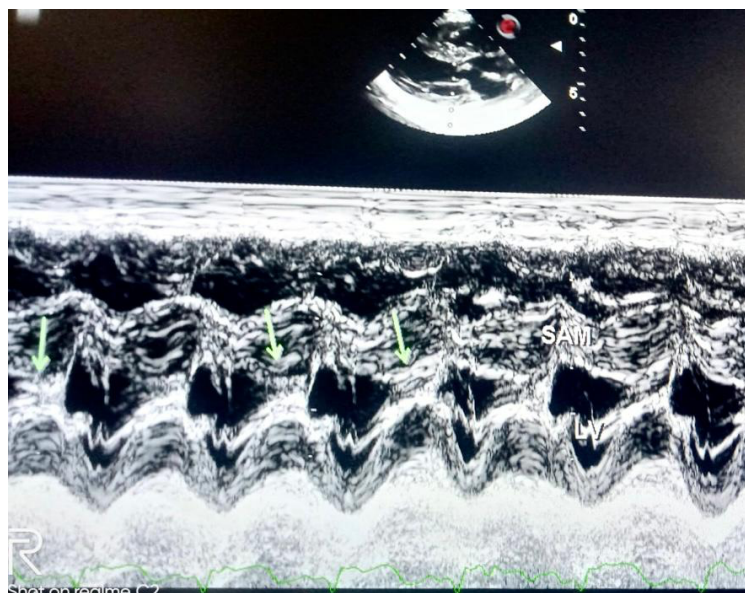


Figure 8: M- mode Echocardiogram at the tip of mitral valve shows the striking presence of systolic anterior motion of mitral leaflets (SAM) towards the ventricular septum causing severe LVOT obstruction.

In the 5CH view, a turbulent mosaic pattern is delineated in the LVOT, signifying a severe LVOT obstruction (Figure 9), with a peak/mean gradient of 73.6/31.4 mmHg (Figure 10). The marked thickness of anterolateral and posterolateral LV was also visualized.

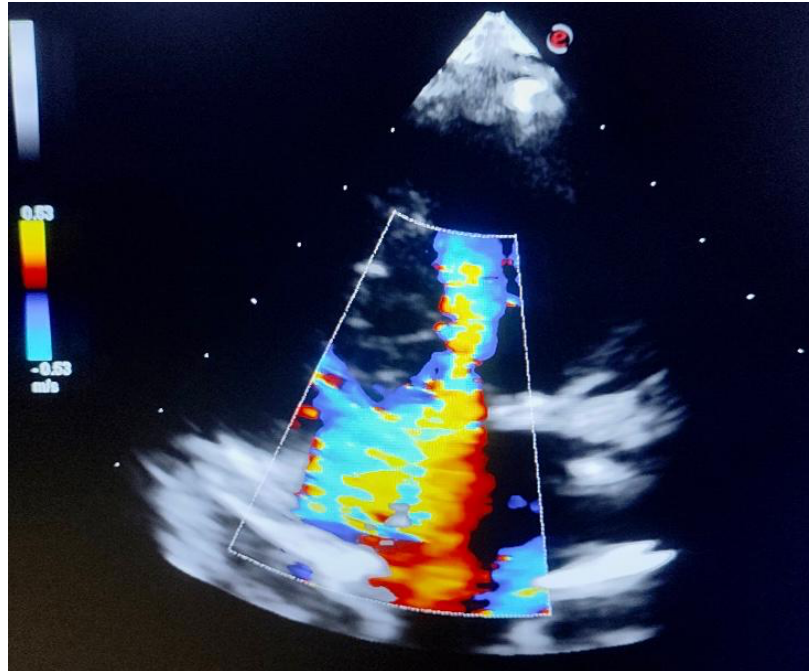


Figure 9: 5CH view demonstrates a distinctive mosaic pattern in the LVOT, suggesting severe obstruction.

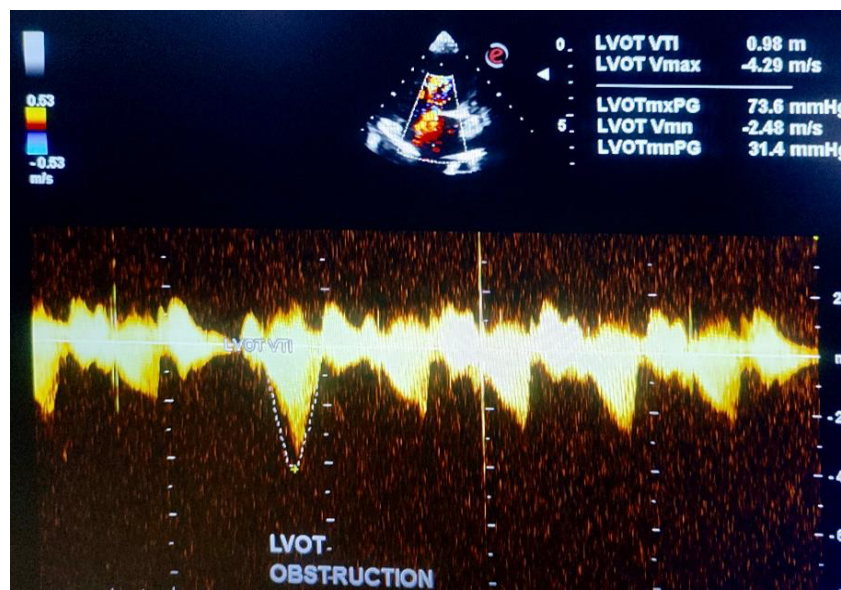


Figure 10: CW Doppler analysis across the LVOT recognizes a peak/ mean gradient of 73.6/31.4 mmHg, indicating a severe obstruction.

Anterior mitral leaflet (AML) and posterior mitral leaflet (PML) were large, thickened and redundant. There was the presence of mild mitral regurgitation (MR), with an eccentric posterior jet measuring 1.34 sqcm. Nonetheless, there was mild dilatation of RV and LV size was small. Furthermore, there was normal biventricular systolic function and LVEF was 75%. For ruling out the presence of anomalous coronary artery origins a 64-slice coronary CT angiography was performed and it demonstrated normal coronary anatomy (Figure 11).

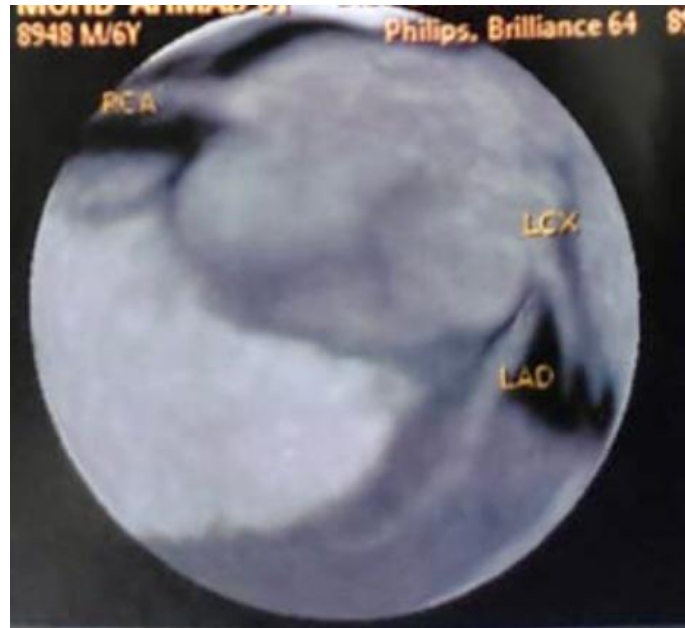


Figure 11: CTA - coronary

Furthermore cardiac CT confirmed our echocardiographic diagnosis of asymmetrical septal hypertrophy and severe LVOT obstruction. The presence of HOCM with severe LVOT obstruction necessitates the need for corrective cardiac surgery and hence the patient was referred to a tertiary care paediatric cardiovascular institute.

Discussion

The combination of Williams Syndrome with exceptionally rare cardiac anomaly of HCM is the highlighting feature of the current case report.

Williams Syndrome – Cardiac Anomalies

Cardiovascular defects are the most common cause of death in patients with WS. [14] Structural cardiovascular abnormalities occur in ~80% of all WS patients [15] and are present in up to 93% of WS patients presenting in the first year of life. [16] Although a number of cardiovascular abnormalities are common to WS, the majority consist of some form of arterial stenosis. [15]

Although arterial stenoses represent the large majority of cardiovascular abnormalities in

patients with WS, a number of other structural cardiac abnormalities are seen with regularity. Ventricular septal defects are present in 4% to 9% of all patients with WS [15], and up to 21% of those presenting in the first year of life. [16] The defects are muscular ventricular septal defects in 75% of children, with the remainder often being conoventricular (perimembranous). [15] Ventricular septal defects in the setting of a complete atrioventricular canal defect [17] and tetralogy of Fallot [18] have been reported.

Aortic valve abnormalities have been described in surgical reports in up to 50% of cases of supravalvular aortic stenosis (SVAS). [19] Bicuspid aortic valve has been reported 5% to 12% of patients with WS. [16]

Mitral valve abnormalities are also common in patients with WS. Mitral valve prolapse is seen in 9% to 27% of patients [18] and is mild in 85% of them. Ebstein anomaly of the tricuspid valve has been reported rarely. [20]

Multiple worldwide studies [4, 8-13] done earlier have demonstrated that HCM is a rare entity associated with WS.

Williams Syndrome - Sudden Cardiac Death

A study showed that the annual incidence of cardiovascular mortality was 1-2% in adult patients with HCM [21] Sudden cardiac death (SCD) is one of the leading causes of death in patients with HCM, which is often correlated with lethal arrhythmias including ventricular tachycardia, ventricular fibrillation and a complete atrioventricular conduction block. The risk of sudden cardiac death in WS is 25 to 100 times greater than that in the general population. [22] The reason of this increased risk of sudden death is not completely understood. More recently, prolongation of the corrected QT interval (QTc) on ECG has been shown to be present in 13% of patients with WS and may contribute to the increased risk of sudden death. [23] In addition, ventricular ectopic complexes and arrhythmias have been correlated with the presence of QTc prolongation in patients with WS, which may indicate a role for microvascular ischemia in the QTc prolongation. [24]

Our patient is a 5year old child and is asymptomatic despite having severe LVOT obstruction and to date had no symptoms of syncope/loss of consciousness or heart failure. Even though our index patient was asymptomatic regardless of severe LVOT obstruction; we recommended early corrective cardiac surgery for the prevention of SCD at a tertiary care pediatric cardiovascular institute.

Conclusion

The coexistence of Williams Syndrome with HCM in childhood is an uncommon condition. Echocardiography, Cardiac CT and Cardiac MRI are essential in the diagnosis of these anomalies. Due to the low risk of complications and a favourable long-term prognosis, surgery has proved to be fundamental in removing the obstruction. Clinicians should recognize early the risk factors of SCD in these patients and then

stratify the risk to make the best decision in patients with WS in association with HCM.

References

1. Moris CB, Mervis CA. Williams syndrome and related disorders. Annual Review of Genomics and Human Genetics. 2000; 1:461-484.
2. Mervis CB, Robinson BF, Bertrand J, Morris CA, Klein-Tasman BP, Armstrong SC. The Williams syndrome cognitive profile. Brain and Cognition. 2000; 44:604-628.
3. Kececioglu D, Kotthoff S, Vogt J. Williams-Beuren syndrome: a 30-year follow-up of natural and postoperative course. European Heart Journal. 1993;14:1458-1464.
4. Eronen M, Peippo M, Hiippala A, et al. Cardiovascular manifestations in 75 patients with Williams's syndrome. Journal of Medical Genetics. 2002;39:554-558.
5. Curran ME, Atkinson DL, Ewart AK, Morris CA, Leppert MF, Keating MT. The elastin gene is disrupted by a translocation associated with supravalvular aortic stenosis. Cell. 1993; 73:159-168.
6. Metcalfe K, Rucka AK, Smoot L, et al. Elastin: mutational spectrum in supravalvular aortic stenosis. European Journal of Human Genetics. 2000; 8:955-963.
7. Frangiskakis JM, Ewart AK, Morris CA, et al. LIM-kinase 1 hemizygoty implicated in impaired visuospatial constructive cognition. Cell. 1996; 86:59-69.
8. Bruno E, Rossi N, Thüer O, Córdoba R, Alday LE. Cardiovascular findings, and clinical course, in patients with Williams's syndrome. Cardiol Young. 2003; 13:532-6.
9. De Rubens Figueroa J, Rodríguez LM, Hach JL, Del Castillo Ruíz V, Martínez HO. Cardiovascular spectrum in Williams-Beuren syndrome: the Mexican experience in 40 patients. Tex Heart Inst J. 2008; 35:279-85.

10. Morris CA, Demsey SA, Leonard CO, Dilts C, Blackburn BL. Natural history of Williams syndrome: physical characteristics. *J Pediatr* 1988; 113:318-26.
11. Kim YM, Yoo SJ, Choi JY, Kim SH, Bae EJ, Lee YT. Natural course of supraaortic stenosis and peripheral pulmonary arterial stenosis in Williams' syndrome. *Cardiol Young* 1999; 9:37-41.
12. Pascual-Castroviejo I, Pascual-Pascual SI, Moreno Granado F, Garcia-Guereta L, Gracia-Bouthelie R, Navarro Torres M, et al. Williams-Beuren syndrome: presentation of 82 cases [in Spanish]. *A Pediatr (Barc)* 2004; 60:530-6.
13. Zalstein E, Moes CA, Musewe NN, Freedom RM. Spectrum of cardiovascular anomalies in Williams-Beuren syndrome. *Pediatr Cardiol* 1991; 12:219-23.
14. Pober BR. Williams-Beuren syndrome. *N Engl J Med*. 2010; 362:239-252.
15. Collins RT 2nd, Kaplan P, Somes GW, Rome JJ. Long-term outcomes of patients with cardiovascular abnormalities and Williams syndrome. *Am J Cardiol*. 2010; 105:874-878.
16. Collins RT 2nd, Kaplan P, Somes GW, Rome JJ. Cardiovascular abnormalities, interventions, and long-term outcomes in infantile Williams's syndrome. *J Pediatr*. 2010; 156:253-258.
17. Nakamoto S, Saga T, Shinohara T. Williams syndrome associated with complete atrioventricular septal defect. *Heart*. 2003;89:e15.
18. Del Pasqua A, Rinelli G, Toscano A, Jacobelli R, Digilio C, Marino B, Saffirio C, Mondillo S, Pasquini L, Sanders SP, de Zorzi A. New findings concerning cardiovascular manifestations emerging from long-term follow-up of 150 patients with the Williams-Beuren-Beuren syndrome. *Cardiol Young*. 2009; 19:563-567.
19. Stamm C, Friehs I, Ho SY, Moran AM, Jonas RA, Del Nido PJ. Congenital supraaortic stenosis: a simple lesion? *Eur J Cardiothorac Surg*. 2001; 19:195-202.
20. Changela V, Maheshwari S, Bhat M. Williams's syndrome and Ebstein's anomaly: a rare association. *Ann Pediatr Cardiol*. 2009; 2:165-166.
21. Ferrero GB, Biamino E, Sorasio L, Banaudi E, Peruzzi L, Forzano S, di Cantogno LV, Silengo MC. Presenting phenotype and clinical evaluation in a cohort of 22 Williams-Beuren syndrome patients. *Eur J Med Genet*. 2007; 50:327-337.
22. Wessel A, Gravenhorst V, Buchhorn R, Gosch A, Patsch CJ, Pankau R. Risk of sudden death in the Williams-Beuren syndrome. *Am J Med Genet A*. 2004;127A:234-237.
23. Collins RT 2nd. Clinical significance of prolonged QTc interval in Williams's syndrome. *Am J Cardiol*. 2011; 108:471-473.
24. Collins RT 2nd, Aziz PF, Swearingen CJ, Kaplan PB. Relation of ventricular ectopic complexes to QTc interval on ambulatory electrocardiograms in Williams syndrome. *Am J Cardiol*. 2012;109:1671-1676.